

**Article History**

Received: 21-02-2023  
Revised: 10-03-2023  
Accepted: 31-03-2023  
Published: 31-03-2023

## Infrared Thermography following Castration, Orectomy and Gastrotomy in Nigerian Indigenous Dogs

\*Saidu, A. M., Olorunfemi, O. J. and Laku, D.

<sup>1</sup>Department of Veterinary Surgery and Radiology, Faculty of Veterinary Medicine, University of Maiduguri, Borno State, Nigeria

\* Author for Correspondence: [abubakarsm51@gmail.com](mailto:abubakarsm51@gmail.com)

**ABSTRACT**

Infrared thermography analyzes changes in the surface temperature of the skin and has been used in companion animals to identify inflammatory processes, neoplasia, pain, and neuropathies. This study evaluated and compared surgical wound surface temperatures in Nigerian Indigenous Dogs (NID). Nigerian indigenous dogs are a medium-sized breed that weighs between 8 to 30 kg with moderate hair length, and a mesocephalic cranial index. The dogs were randomly allocated into groups A, B, and C for castration, orectomy, and gastrotomy, respectively. The wound surface temperature (WST) in the NID that underwent gastrotomy were significantly higher particularly at 18-48 h compared with Pre and other sampling periods within the group. It was also found that, at 0 h versus 48 h, 18 h versus 48 h, week 1 versus 18h; 24h; 48h; and 72h showed significant ( $p < 0.05$ ) differences among NID subjected to gastrotomy (group C). However, the WST of NID subjected to castration and orectomy were significantly higher than that of gastrotomy. At 48 and 72 h, and week 1, the WST of NID in orectomy also known as ear cropping (group B) and castration (group A) were significantly ( $p < 0.05$ ) higher than that of gastrotomy (Group C). Thermography of the surgical wounds aided postoperative wound management in the NID that underwent castration, orectomy and gastrotomy. Hence, the study suggests that guided WST with the aid of infrared thermography could be deployed as a useful tool to aid post operative wound management.

**Keywords:** Dog; Ear Cropping; Gastrotomy; Thermography; Orectomy

**INTRODUCTION**

The concept of body heat as a marker of disease has a long history in clinical practice (DeWitt *et al.*, 2017). The use of thermometry was previously restricted to core or systemic body temperature measures through the approximation of mucosa temperature readings with the aid of clinical or rectal thermometers. These thermal measures expanded beyond core body temperature readings following recent advancements in material science and technology (Meola and Carlomagno, 2004). The surface temperature of the wound is one of the clinical pointers used to provide significant diagnostic information regarding wound healing (Webb *et al.*, 1993).

The back of the hand has been used to assess one of the signs of inflammation (warmth/heat) at injury sites. However, this assessment is subjective. Thermal imaging offers an objective and repeatable measure of wound surface temperature (SWT) for clinical decision making (Ramirez-GarciaLuna *et al.*, 2022). The product of this remains relative, however, absolute values as could be obtained with thermal imaging camera would have a more surrounding clinical relevance that could aid early detection of circulatory problems, inflammation, poor wound healing and

possibly give a clue into possible systemic conditions, without having to come into touch with the animal or the wound bed which minimizes the possibility of wound contamination (Ramirez-GarciaLuna *et al.*, 2022). This method is also patient-friendly, accurate and offers a clear picture of the distribution of a patient's body temperature, establishing the animal's surface temperature using the infrared thermography. The potential of thermography in veterinary medicine has been investigated in many of the same medical fields as in human medicine and tested on a variety of species, including horses (Soroko *et al.*, 2013, Redaelli *et al.*, 2014) cattle (Stewart *et al.*, 2007, Rainwater-Lovett *et al.*, 2009), wild animals (Cilulko *et al.*, 2013) and dogs and cats (Vainionpää, 2014). Thermography is widely practiced in equine medicine and studies on thermal imaging were mostly focused on the potentials of thermography in early identification and diagnosis of orthopedic injuries and lameness in horses (Turner, 2001). Furthermore, application of thermography in detection of illegal performance enhancing techniques (Van Hoogmoed and Snyder, 2002) has been explored. These include early detection of distal limb cast sores (Levet *et al.*, 2009), back pain diagnosis (Fonseca *et al.*, 2006), saddle assessment (Arruda *et al.*, 2011) and stress (Dai *et al.*, 2015) amongst others. Its

potential application in small animal practice has received less attention in the last decades, however, information on application of thermography in small animal medicine is now available. With the aim of facilitating identification and diagnosis of pathological processes like disc hernia, keratoconjunctivitis sicca, and mammary tumours, attempts have been made to validate thermography data from specific regions of interest (ROI) such as the thoracolumbar area (Grossbard *et al.*, 2014), ocular surface (Biondi *et al.*, 2015) and mammary glands (Pavelski *et al.*, 2015). Grossbard *et al.* (2014) investigated the potentials of thermography as a screening tool to detect thoracolumbar disc hernia, while Vainionpää *et al.* (2012) investigated its use in the early detection of muscle injury. Researchers have also considered the potential use of thermography to detect painful conditions in cats (Vainionpää *et al.*, 2013). While contemporary medicine and surgery support and seek non-invasive or minimally invasive approaches for diagnosis and therapeutics, infrared thermography is a non-invasive method of monitoring wound conditions to establish wound surface temperature that may guide postoperative wound care. This study evaluated and compared the wound bed thermal image surface temperature at varied time points following castration, ear cropping and gastrotomy in Nigeria indigenous dogs. The Nigerian indigenous dog (NID) is a medium to large-sized working dog breed that weighs between 8 to 30 kg with moderate hair length and have a mesocephalic cranial index (Bappah *et al.*, 2019a, Bappah *et al.*, 2019b). Although the true origin of this breed is unknown, it is usually assumed that it originated in Nigeria. The Nigerian Shepherd Dog is the official name in English (sometimes abbreviated as NSD) and locally, Kare, Ekuke, Nkita as many will call it. Nigeria Shepherds are a relatively old dog breed whose origins are unclear. They are working dogs that belong to the herding group and are popular among hunters and farmers owing to their strength, intelligence, trainability, and obedience (Pets - Nairaland, 2023).

The study aimed at assessing the wound surface temperatures following ear cropping, castration and gastrotomy at different time points to establish basis which may aid surgeons' informed decisions of post-operative care based on the thermal image surface temperature changes in the NID to guide clinical decisions.

## MATERIALS AND METHODS

### Study Design

Data was collected from fifteen Nigerian indigenous dogs weighing 10-20 kg, provided by the Department of Veterinary Surgery and Radiology, Faculty of Veterinary Medicine, University of Maiduguri.

Prior to the surgery, the animals were acclimatized in a kennel for three weeks at the Department of Veterinary Surgery and Radiology, University of Maiduguri. The dogs were fed rice, meat and fish three times daily except at periods specified for fasting as preoperative dietary restrictions. Clean drinking water was provided *ad libitum*.

Each patient underwent a pre-operative hematological assessment to validate apparently healthy status, as fit for the experiment. The dogs were randomly assigned to groups A, B

and C, and underwent castration, ear cropping and gastrotomy, respectively.

### Ethical Statement

Approval for the study was granted by the Faculty Board of Veterinary Medicine, Faculty of Veterinary Medicine, 2020/2021 academic session to the Department of Veterinary Surgery and Radiology, University of Maiduguri, Maiduguri, Borno State, Nigeria.

### Thermal Visible Image

An RX-350 camera (A-BF, mainland, China) for thermal imaging with resolution of 80x60 IR Pixels and temperature measurement range of -20°C to 400°C (-4°F to 752°F) was deployed for the study. It is composed of a Pouvoir 2 LA7, 13MP rear Camera (Tecno, Hong Kong, China) with dual flash that captures and produce image of surgical wound beds for interpretation of its thermal image. To standardize optical effects when using the Tecno Pouvoir 2 camera, a distance of 10 cm - 15 cm distance from the camera lens to the object was maintained whenever clarity was achieved.

### Preoperative Preparation and Anaesthetic Protocol

The dogs were premedicated with atropine sulphate 0.02mg/kg (BIO-ATROPIN®, HCMV- Vietnam) and xylazine hydrochloride 1mg/kg (XYL-M2®, VMD – Hoge Mauw 900, Belgium). The surgical sites were shaved, and scrubbed with 0.2% chlorhexidine gluconate (Savlon®, vervaading deur, Johnson and Johnson (pty) Ltd, London) and povidone-iodine (Sawke- 10%®, Jawa International Limited, Lagos, Nigeria) was finally applied. To achieve anaesthesia, total intravenous anaesthesia was instituted (TIVA) using thiopentone sodium (Thiopentaman®, Naman pharma drugs, Princess Street, Mumbai, India) 7mg/kg, following patient stabilization with IV infusion of normal saline 0.9%.

### Surgical Procedures

#### Otectomy (Ear Cropping)

Following general anaesthesia, the dogs were restrained in sternal recumbency, and the surgical sites draped. Haemostatic forceps were placed around the pinna until a triangular shape was achieved (Busch, 1983) that allowed the caudal and rostral borders of helix to be trimmed (Figure 1), as described by Willot (1980) and Matera *et al.* (1989).

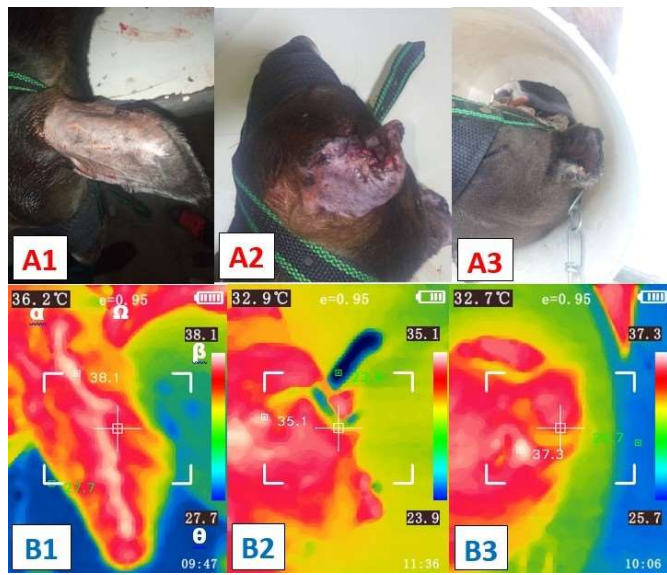
#### Castration

Following general anaesthesia, the dogs were placed on dorsal recumbency such that the hind limbs were apart exposing the inguinal region and drape was applied allowing access to only the surgical field of interest. A prescrotal castration as described by (Woodruff *et al.*, 2015) and (Brunn, 2022) was deployed (Figure 2).

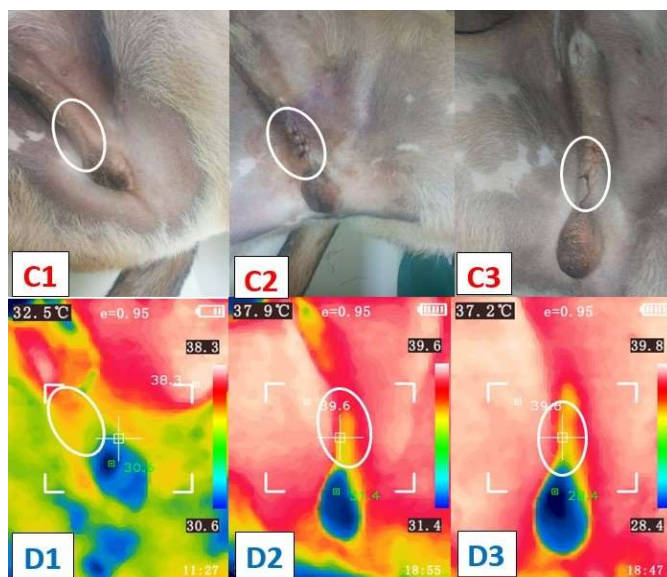
#### Gastrotomy

Under general anaesthesia, dogs were placed on dorsal recumbence. The surgical site was draped, and a mid-ventral abdominal incision was made through the skin, linea alba, and peritoneum such that the abdominal cavity was accessed and

gastrotomy was achieved as described by Yoon *et al.* (2009), Figure. 3



**Figure 1:** Photo (A) and thermal windows (B) of the pinna Pre- (A1, B1), 0h after (A2, B2), and 2 weeks after (A3, B3) otcetomy (ear cropping), illustrating emissivity (omega), lowest temperature (theta), highest temperature (beta), and central temperature (alpha) in the Nigeria indigenous dog.




**Figure 2:** Photos (C) and thermal windows (D) of the pre-scrotal surgical site (white circle) Pre (C1, D1), 0h after (C2, D2), and 2 weeks after (C3, D3) castration in the Nigeria indigenous dog.

**Post-operative care**

Antibiosis was achieved via intramuscular injection of amoxicillin trihydrate (Amoxinject LA<sup>®</sup>) 15mg/kg while flunixin meglumine (Bremaflixin<sup>®</sup> Brema pharma GmbH, 34414 warburg, Germany) 2.2mg/kg was administered intramuscularly for analgesia. Daily dressing of the surgical wounds was achieved through aseptic cleaning with topical 0.2% chlorhexidine gluconate (Savlon<sup>®</sup>, vervaading deur, Johnson and Johnson (pty) Ltd, London), povidone-iodine (Sawke- 10%<sup>®</sup>, Jawa International Limited, Lagos, Nigeria) and oxytetracycline

spray (Hebei Huabang Biotechnology Co., Ltd. Shijiazhuang, China).



**Figure 3:** Photo (E) and thermal (F) windows of the anterior midline incision (white rectangle) Pre (E1, F1), Intra (E2, F2), 0h (E3, F3), and 2 weeks (E4, F4) in the Nigeria indigenous dog subjected to gastrotomy

**The application of the thermal image camera for evaluation of wound surface temperature following otcetomy, castration and gastrotomy.**

The emissivity of the thermal imaging camera was set at 0.95. The device was held by its handle and the thermal imaging sensor was directed and focused on the object such that the image was viewed on the LCD display. The trigger button was pressed to capture the thermal image after satisfactorily having images on the LCD monitor displayed information on emissivity (Ω), lowest temperature (θ), highest temperature (β), and central temperature (α); (Figure 1; B1).

Measurement of surface temperature using the thermal imaging camera were taken before and immediately after (0 hour) for each procedure, then 6 hourly for 24 hours then after 48 hours, 72 hours, week 1, and week 2 for all the three Surgical procedures. Photographic documentation of wound site and thermal imaging was recorded. Images were taken with a Tecno Pouvoir 2 (LA7) camera using the distances mentioned above. The dogs were restrained on an examination tables and images were captured with the patients sternal or dorsal recumbency depending on anatomical site of wound and a 15-30 cm distance between the object and camera were ensured for a satisfactory image quality.

**Data analysis**

The Mean ± Standard error (SE) periodic thermal imaging temperature for all the groups were established through row statistic of grouped analyses using GraphPad Prism version 9.4.1. for Windows, © 2022 GraphPad Software, San Diego, California, USA, www.graphpad.com. A One-Way Repeated measures ANOVA was employed to compare the surface temperature within groups with Tukey's multiple comparisons post-hoc test. To compare the three groups, Two-Way Repeated measures

ANOVA followed by Tukey's multiple comparison post-hoc test was used. Statistical significance was defined at  $p < 0.05$ .

## RESULTS

The mean  $\pm$  SE pre-surgical thermal surface temperature for group A was  $33.30 \pm 0.61^\circ\text{C}$  while that of group B read  $34.76 \pm 1.10^\circ\text{C}$ . These values when compared to the respective values at

different sampling periods within each group revealed non-significant ( $p > 0.05$ ) difference. Similarly, in group C, there was no significant ( $p > 0.05$ ) difference between Pre ( $33.92 \pm 1.08^\circ\text{C}$ ) and other sampling periods. However, the mean  $\pm$  SE thermal surface temperatures increased significantly ( $p < 0.05$ ) between 0 h & 48 h, 18 h & 48 h, week 1 & 18h; 24h; 48h; 72h, (Table 1).

**Table 1:** Mean  $\pm$  SE of wound surface temperature following castration, Otcetomy and gastrotomy in Nigerian Indigenous Dogs.

GROUPS	SAMPLING PERIODS									
	PRE	0HR	6HR	12HR	18HR	24HR	48 HR	72HR	WK1	WK2
<b>A (Castration)</b>	$33.30 \pm 0.61$	$33.34 \pm 0.86$	$35.64 \pm 0.57$	$33.60 \pm 0.91$	$35.10 \pm 0.80$	$35.14 \pm 0.38$	$35.82 \pm 0.61$	$35.36 \pm 0.88$	$35.24 \pm 0.64_{\alpha\beta}$	$32.84 \pm 1.27$
<b>B (Otcetomy)</b>	$34.76 \pm 1.10$	$33.78 \pm 0.86$	$35.34 \pm 1.13$	$33.94 \pm 0.87$	$34.58 \pm 0.49$	$35.30 \pm 1.16$	$36.94 \pm 0.31_{\alpha\beta}$	$35.34 \pm 0.47_{\alpha\beta}$	$36.58 \pm 0.29_{\alpha\beta}$	$34.66 \pm 0.74$
<b>C (Gastrotomy)</b>	$33.92 \pm 1.08$	$31.18 \pm 0.86^a$	$32.70 \pm 1.02$	$34.48 \pm 0.67$	$32.98 \pm 0.67^{a,b}$	$34.10 \pm 0.55^{a,b,c}$	$35.36 \pm 0.33^c_{\Omega\mu}$	$32.90 \pm 0.58^{a,b}_{\Omega\mu}$	$30.04 \pm 0.51^{a,d}_{\Omega\mu}$	$36.00 \pm 1.37$

Values with different superscript in alphabets within rows and those with different symbols between columns significantly ( $p < 0.05$ ) differ

The mean  $\pm$  SE pre-surgical thermal imaging temperature of groups A, B, and C were  $33.30 \pm 0.61$ ,  $34.76 \pm 1.10$ , and  $33.92 \pm 1.08^\circ\text{C}$ , respectively. Comparisons between groups A, B and C revealed that at 24 hours, the surgical thermal imaging temperature steadily rose to  $35.14 \pm 0.38$ ,  $35.30 \pm 1.16$ , and  $34.10 \pm 0.55^\circ\text{C}$ , respectively, but were not significant ( $p > 0.05$ ). At 48 hours post-surgery, group B had significantly ( $p < 0.05$ ) higher values than Group C. Similarly, at 72 hours post-surgery, group B recorded significantly ( $p < 0.05$ ) higher values than that of group C. Likewise at week 1, group A significantly ( $p < 0.01$ ) recorded higher values than group C, the values of group B was also observed to have significantly ( $p < 0.001$ ) rose than group C (Table 1).

## DISCUSSION

Infrared thermography following otcetomy, castration, and gastrotomy in Nigerian Indigenous Dogs (NID) revealed changes in the wound surface temperature (WST), notwithstanding that the study appears to be the first in the NIDs.

The significantly higher mean  $\pm$  SE thermal surface temperature within group C at 48 h than at 0 h and 18 h reflects extensive inflammatory process following the invasive nature of gastrotomy in contrast surgeries as could be opposed to minimally invasive procedures. The events at these time points and until the WST peaked at 48 h through 72 h suggest cellular responses associated with inflammation, as similarly observed by Szpaderska and DiPietro (2005) that evaluated inflammation in surgical wounds, and as was further detailed by Eugster *et al.* (2004), who gave information on surgical site infection in hospitals and delineated variables of inflammation in surgical patients as well as suggested appropriate preventative actions for patients at risk. The time for body response remains of essence as studies such as the ones by McCafferty *et al.* (2007) and (McCafferty *et al.*, 2011) demonstrated that metabolic response rate that last for several hours and even up to 24 hours could be minimal or high depending on the degree of the procedure and body site or location. The Significant changes in values of the WST of gastrotomy in group C could clearly be linked to the established fact that major procedures are associated with

hypermetabolic states known to have increased WST (Wang *et al.*, 2010, Kanitakis, 2002). This finding was further corroborated by Lin *et al.* (2021), who observed a high wound temperature to be positively correlated with wound healing following infrared thermography and can objectively serve as indicators for assessing pressure-ulcer healing.

The thermal imaging temperatures in group B was higher than group C at 48 h, and 72 h, implying higher pain and inflammatory response in group B than group C. Likewise group B maintained higher significance up to week 1, group A was also higher than that of group C at this time point. These findings agree with the work of Walters *et al.* (2000), that reported thresholds for painful cutaneous sensation during stimulation by millimeter wavelength microwaves, together with an analysis of the thermal response of skin in terms of a simple heat conduction model. The significantly high changes in the values of WST within group C and in the comparisons of groups A and B agrees with the findings of Gethin *et al.* (2021) in their study that reported that normal thermal imaging temperature of wound beds to range between  $30.2^\circ\text{C}$  and  $33.0^\circ\text{C}$  using the thermographic camera. Changes in thermal imaging temperatures at these surgical sites may be associated with the disruption in sympathetic autonomic control which can cause an increase or decrease in blood flow as determinants of WST changes (Marino, 2011). The stress response to surgery is characterized by an increased secretion of pituitary hormones and activation of the sympathetic nervous system (SNS). This sympathetic nervous system activation increases efferent signals to vascular smooth muscle, thereby increasing arterial blood pressure and blood flow to surgical site (Cusack and Buggy, 2020), detected by the infrared thermography expressed as increased or decreased blood flow, a common determinant of inflammatory response.

Furthermore, group B that had otcetomy, the pinna is surrounded with numerous nerve endings, majorly, a sensory innervation of the pinna by four nerves, the auriculotemporal branch of the trigeminal nerve, lateral internal auricular branch of the facial nerve, which may contain predominantly vagal nerve fibers, and second cervical nerve (Whalen and Kitchell, 1983, Cole, 2009)



and changes in WST may be related to sensory innervations at surgical sites. This could suggest why group B (otectomy) had significantly higher values than group C that had gastrotomy as observed in this study. Likewise castration in group A dogs characterized with high innervations of the perinium as well as the scrotum, derived from the branches of four nerves, the genitofemoral, pudendal, posterior femoral cutaneous, and ilioinguinal nerves (Garcia and Sajjad, 2019) could suggest why group A had significantly higher values than Group C. Whereas in gastrotomy, the skin of the abdomen is innervated by dorsal and lateral cutaneous branches of spinal nerves T12 through L3 (Bailey *et al.*, 1984) and the Linea alba generally with limited blood supply and innervations. According to Walters *et al.* (2000), surface temperature increases with pain, however, skin surface temperature has been observed to be higher over organs with high metabolic rates rather than those at rest, as well as over muscles rather than tendons or bones (Wang *et al.*, 2010) (Kanitakis, 2002) and this could explain why significantly higher WST in the otectomy and castrated dogs over those that had gastrotomy. If nociception remains a factor, this could add to the observed lower significant difference in group C than those of Group A and B for the facts that there could be fewer nociception around the Linea alba.

### Conclusion

Thermography following castration, otectomy and gastrotomy in NID was linked with substantial changes in their respective WST values, implying that thermography of surgical wounds might aid postoperative wound care in NID. Hence, the study suggest that guided WST can be deployed as a useful tool to aid post operative wound management.

### Conflict of Interest

The authors have no conflict of interest to declare.

### Authors' Contribution

AMS conceptualized and designed the experiment, participated in the surgical procedures, and analyzed and interpreted the data, as well as provided critical reviews of the manuscript. JOO collected the data, wrote the literature, and participated in critical reviews of the manuscript. LD participated in the surgical procedures, data interpretation, and critical reviews of the manuscript. All authors have proofread and approved the final manuscript.

### REFERENCES

Arruda, T. Z., Brass, K. E. and Flavio, D. (2011). Thermographic assessment of saddles used on jumping horses. *Journal of Equine Veterinary Science*, 31 (11): 625-629 DOI: <http://dx.doi.org/10.1016/j.jevs.2011.05.011>.

Bailey, C., Kitchell, R., Haghighi, S. and Johnson, R. (1984). Cutaneous innervation of the thorax and abdomen of the dog. *American Journal of Veterinary Research*, 45 (9): 1689-1698.

Bappah, M., Awasum, C., Chom, N., Lawal, M., Bada, A., Ochube, G., Umar, M., Hassan, A. and Hassan, F. (2019a). Relationship between ultrasonographic kidney bipolar length and body weight in normal Nigerian indigenous dogs. *Savannah Veterinary Journal*, 2 (2): 24-28 DOI: 10.36759/svj.2019.037.

Bappah, M., Awasum, C., Chom, N., Lawal, M., Bello, U., Bada, A., Idris, S. and Ochube, G. (2019b). Correlation of ultrasonographic renal volume with modified body

mass index in Nigerian indigenous dogs. *Sokoto Journal of Veterinary Sciences*, 17 (3): 9-16. DOI: 10.4314/sokjvs.v17i3.2.

Biondi, F., Dornbusch, P. T., Sampaio, M. and Montiani-Ferreira, F. (2015). Infrared ocular thermography in dogs with and without keratoconjunctivitis sicca. *Veterinary Ophthalmology*, 18 (1): 28-34 DOI: <http://dx.doi.org/10.1111/vop.12086>.

Brunn, A. (2022). Surgical castration in dogs: does the incision approach influence postoperative recovery? *Veterinary Evidence*, 7 (4): DOI: [doi.org/10.18849/ve.v7i4.587](https://doi.org/10.18849/ve.v7i4.587).

Busch, T. (1983). Canine ear cropping. *New Zealand Veterinary Journal*, 31 (11): DOI: [doi.org/10.1080/00480169.1983.35032](https://doi.org/10.1080/00480169.1983.35032).

Cilulko, J., Janiszewski, P., Bogdaszewski, M. and Szczygielska, E. (2013). Infrared thermal imaging in studies of wild animals. *European Journal of Wildlife Research*, 59 (1): 17-23 DOI: <http://dx.doi.org/10.1007/s10344-012-0688-1>.

Cole, L. K. (2009). Anatomy and physiology of the canine ear. *Veterinary Dermatology*, 20 (5-6): 412-421 DOI: <http://dx.doi.org/10.1111/j.1365-3164.2009.00849.x>.

Cusack, B. and Buggy, D. (2020). Anaesthesia, analgesia, and the surgical stress response. *BJA education*, 20 (9): 321 DOI: <http://dx.doi.org/10.1016/j.bjae.2020.04.006>.

Dai, F., Cogi, N. H., Heinzl, E. U. L., Dalla Costa, E., Canali, E. and Minero, M. (2015). Validation of a fear test in sport horses using infrared thermography. *Journal of Veterinary Behavior*, 10 (2): 128-136 DOI: <http://dx.doi.org/10.1016/j.jvbeh.2014.12.001>.

Dewitt, S., Chavez, S. A., Perkins, J., Long, B. and Koyfman, A. (2017). Evaluation of fever in the emergency department. *The American Journal of Emergency Medicine*, 35 (11): 1755-1758 DOI: [doi.org/10.1016/j.ajem.2017.08.030](https://doi.org/10.1016/j.ajem.2017.08.030).

Eugster, S., Schawalder, P., Gaschen, F. and Boerlin, P. (2004). A prospective study of postoperative surgical site infections in dogs and cats. *Veterinary surgery*, 33 (5): 542-550 DOI: [doi.org/10.1111/j.1532-950X.2004.04076.x](https://doi.org/10.1111/j.1532-950X.2004.04076.x).

Fonseca, B., Alves, A. L. G., Nicoletti, J., Thomassian, A., Hussni, C. A. and Mikail, S. (2006). Thermography and ultrasonography in back pain diagnosis of equine athletes. *Journal of Equine Veterinary Science*, 26 (11): 507-516 DOI: <http://dx.doi.org/10.1016/j.jevs.2006.09.007>.

Garcia, R. A. and Sajjad, H. (2019). Anatomy, abdomen and pelvis, scrotum. In: StatPearls [Internet]. Treasure Island (FL) [Online]. [Accessed 2022 Jan–2022 Jul 25].

Gethin, G., Ivory, J. D., Sezgin, D., Muller, H., O'connor, G. and Vellinga, A. (2021). What is the “normal” wound bed temperature? A scoping review and new hypothesis. *Wound Repair Regeneration*, 29 (5): 843-847 DOI: <http://dx.doi.org/10.1111/wrr.12930>.

Grossbard, B. P., Loughin, C. A., Marino, D. J., Marino, L. J., Sackman, J., Umbaugh, S. E., Solt, P. S., Afruz, J., Leandro, P. and Lesser, M. L. (2014). Medical infrared imaging (thermography) of type I thoracolumbar disk disease in chondrodystrophic dogs. *Veterinary Surgery*, 43 (7): 869-876 DOI: <http://dx.doi.org/10.1111/j.1532-950X.2014.12239.x>.

- Kanitakis, J. (2002). Anatomy, histology and immunohistochemistry of normal human skin. *European Journal of Dermatology* 12 (4): 390-399 DOI: 12095893.
- Levet, T., Martens, A., Devisscher, L., Duchateau, L., Bogaert, L. and Vlamincx, L. (2009). Distal limb cast sores in horses: risk factors and early detection using thermography. *Equine Veterinary Journal*, 41 (1): 18-23 DOI: <http://dx.doi.org/10.2746/042516408X343046>.
- Lin, Y.H., Chen, Y.C., Cheng, K.S., Yu, P.J., Wang, J.L. and Ko, N.Y. (2021). Higher periwound temperature associated with wound healing of pressure ulcers detected by infrared thermography. *Journal of Clinical Medicine*, 10 (13): 2883.
- Marino, D. J. (2011). Medical infrared imaging (thermography) in veterinary neurology. *American College of Veterinary Surgeons, Chicago, Chicago*. 244-245.
- Matera, A., Pezzutti Holzchuh, M., Spicciati, W. and Elias Randi, R. (1989). Simplified surgical technique of ear cropping. *Brazilian journal of veterinary research and animal science*, 26 (2): 213-221 DOI: vti-726949.
- Mccafferty, D., Gilbert, C., Paterson, W., Pomeroy, P., Thompson, D., Currie, J. and Ancel, A. (2011). Estimating metabolic heat loss in birds and mammals by combining infrared thermography with biophysical modelling. *Comparative Biochemistry Physiology Part A: Molecular Integrative Physiology*, 158 (3): 337-345 DOI: <http://dx.doi.org/10.1016/j.cbpa.2010.09.012>.
- Mccafferty, D. J., Currie, J. and Sparling, C. E. (2007). The effect of instrument attachment on the surface temperature of juvenile grey seals (*Halichoerus grypus*) as measured by infrared thermography. *Deep Sea Research Part II: Topical Studies in Oceanography*, 54 (3-4): 424-436 DOI: <http://dx.doi.org/10.1016/j.dsr2.2006.11.019>.
- Meola, C. and Carlomagno, G. M. (2004). Recent advances in the use of infrared thermography. *Measurement science technology*, 15 (9): R27 DOI: <http://dx.doi.org/10.1088/0957-0233/15/9/R01>.
- Pavelski, M., Silva, D., Leite, N., Junior, D., De Sousa, R., Guérios, S. and Dornbusch, P. (2015). Infrared Thermography in Dogs with Mammary Tumors and Healthy Dogs. *Journal of veterinary internal medicine*, 29 (6): 1578-1583 DOI: <https://doi.org/10.1111/jvim.13597>.
- Pets - Nairaland, F. (2023). All About the Nigerian Shepherd Dog (Ekuke, Nkita) [Online]. Nigeria: Nairaland. Available: <https://www.nairaland.com/4747625/all-nigerian-shepherd-dog-ekuke> [Accessed 24/03/2023].
- Rainwater-Lovett, K., Pacheco, J. M., Packer, C. and Rodriguez, L. L. (2009). Detection of foot-and-mouth disease virus infected cattle using infrared thermography. *The Veterinary Journal*, 180 (3): 317-324 DOI: <http://dx.doi.org/10.1016/j.tvjl.2008.01.003>.
- Ramirez-Garcialuna, J. L., Rangel-Berridi, K., Bartlett, R., Fraser, R. D. and Martinez-Jimenez, M. A. (2022). Use of Infrared Thermal Imaging for Assessing Acute Inflammatory Changes: A Case Series. *Cureus*, 14 (9): DOI: 10.7759/cureus.28980.
- Redaelli, V., Bergero, D., Zucca, E., Ferrucci, F., Costa, L. N., Crosta, L. and Luzi, F. (2014). Use of thermography techniques in equines: principles and applications. *Journal of Equine Veterinary Science*, 34 (3): 345-350 DOI: <http://dx.doi.org/10.1016/j.jevs.2013.07.007>.
- Soroko, M., Henklewski, R., Filipowski, H. and Jodkowska, E. (2013). The effectiveness of thermographic analysis in equine orthopedics. *Journal of equine veterinary science*, 33 (9): 760-762 DOI: <http://dx.doi.org/10.1016/j.jevs.2012.11.009>.
- Stewart, M., Webster, J., Verkerk, G., Schaefer, A., Colyn, J. and Stafford, K. (2007). Non-invasive measurement of stress in dairy cows using infrared thermography. *Physiology behaviour*, 92 (3): 520-525 DOI: <http://dx.doi.org/10.1016/j.physbeh.2007.04.034>.
- Szpadarska, A. M. and Dipietro, L. A. (2005). Inflammation in surgical wound healing: friend or foe? *Surgery*, 137 (5): 571-573 DOI: [doi.org/10.1016/j.surg.2005.01.006](https://doi.org/10.1016/j.surg.2005.01.006).
- Turner, T. A. (2001). Diagnostic thermography. *Veterinary Clinics of North America: Equine Practice*, 17 (1): 95-114.
- Vainionpää, M. (2014). Thermographic imaging in cats and dogs: usability as a clinical method. PhD Thesis, University of Helsinki.
- Vainionpää, M., Tienhaara, E.-P., Raekallio, M., Junnila, J., Snellman, M. and Vainio, O. (2012). Thermographic Imaging of the Superficial Temperature in Racing Greyhounds before and after the Race. *The Scientific World Journal*, 2012 DOI: <http://dx.doi.org/10.1100/2012/182749>.
- Vainionpää, M. H., Raekallio, M. R., Junnila, J. J., Hielm-Björkman, A. K., Snellman, M. P. and Vainio, O. M. (2013). A comparison of thermographic imaging, physical examination and modified questionnaire as an instrument to assess painful conditions in cats. *Journal of Feline Medicine Surgery*, 15 (2): 124-131 DOI: <http://dx.doi.org/10.1177/1098612X12463926>.
- Van Hoogmoed, L. M. and Snyder, J. R. (2002). Use of infrared thermography to detect injections and palmar digital neurectomy in horses. *The Veterinary Journal*, 164 (2): 129-141 DOI: <http://dx.doi.org/10.1053/tvj.2002.0719>.
- Walters, T. J., Blick, D. W., Johnson, L. R., Adair, E. R. and Foster, K. R. (2000). Heating and pain sensation produced in human skin by millimeter waves: comparison to a simple thermal model. *Health physics*, 78 (3): 259-267 DOI: <http://dx.doi.org/10.1097/00004032-200003000-00003>.
- Wang, Z., Ying, Z., Bosy-Westphal, A., Zhang, J., Schautz, B., Later, W., Heymsfield, S. B. and Müller, M. (2010). Specific metabolic rates of major organs and tissues across adulthood: evaluation by mechanistic model of resting energy expenditure. *The American journal of clinical nutrition*, 92 (6): 1369-1377 DOI: 10.3945/ajcn.2010.29885.
- Webb, P. I., Speakman, J. R. and Racey, P. A. (1993). The implication of small reductions in body temperature for radiant and convective heat loss in resting endothermic brown long-eared bats (*Plecotus auritus*). *Journal of thermal biology*, 18 (3): 131-135.

- Whalen, L. and Kitchell, R. (1983). Electrophysiologic and behavioral studies of the cutaneous nerves of the concave surface of the pinna and the external ear canal of the dog. *American Journal of Veterinary Research*, 44 (4): 628-634.
- Willot, M. (1980). Otectomy (ear cropping) of Briard dogs. *Point Veterinaire*, 10 (48): 16-25 DOI: 19802259172.
- Woodruff, K., Rigdon-Brestle, K., Bushby, P., Wills, R. and Huston, C. (2015). Scrotal castration versus prescrotal castration in dogs. *Veterinary Medicine*, 110 (5): 131-135.
- Yoon, H. Y., Kang, M. G. and Jeong, S. W. (2009). Gastrotomy approach retrieval of esophageal foreign body using long forceps technique in five dogs. *Journal of Veterinary Clinics*, 26 (6): 628-631.