



Article History

Received: 7th April, 2020

Revised: 7th May, 2020

Accepted: 16th May, 2020

Published: 30th June, 2020

Management of Diffuse Necrotic Cutaneous Wound in a Dog

^{1*}Muhammad, S. T., ²Abdurrahman. M., ³Avazi, D. O., ¹Usman, B., ¹Emmanuel, E. G.,
⁴Sulaiman, M. H., ⁵Mamman, P. H., ¹Babashani, M., ¹Jahun, B. M., ⁶Mohammed, B.,
²Awasm, C. A., ²Hassan, A. Z. and ¹Adawa, D. A. Y.

¹Veterinary Teaching Hospital, Ahmadu Bello University Zaria, Nigeria

²Department of Veterinary Surgery and Radiology, Ahmadu Bello University Zaria, Nigeria

³Department of Veterinary Medicine, Surgery and Radiology, University of Jos, Nigeria

⁴Department of Veterinary Anatomy, Ahmadu Bello University Zaria, Nigeria

⁵Department of Veterinary Microbiology, Ahmadu Bello University Zaria, Nigeria

⁶Department of Veterinary Pathology, Ahmadu Bello University Zaria, Nigeria

* Author for Correspondence: tmsaidu@abu.edu.ng

ABSTRACT

A one-year-old male Terrier dog weighing 22 kg was presented to the Ahmadu Bello University Veterinary Teaching Hospital (ABUVTH), Zaria, Nigeria, with complaints of sloughing of the skin and purulent discharges from an injured (sloughed) shoulder. Clinical examination revealed normal vital parameters, extensive necrotized skin on the dorsum extending from loin to the right shoulder and enlarged superficial lymph nodes. Blood and wound swab samples were evaluated in the clinical haematology and Microbiology Laboratories of the ABUVTH, respectively. The Pathology result showed leucocytosis due to neutrophilia and monocytosis. *Staphylococcus aureus* was isolated from the wound swab. The wound was managed by wet-to-dry bandaging technique using topical antiseptics (Para-chloroaniline solution, chlorhexidine and povidone iodine), improvised non-adhesive protective membrane (polyethylene) applied at the wound-bandage interface, bandages along with adhesive tape and systemic antibiotics. Healing occurred uneventfully within 6 weeks of the intervention. The paper discusses the detail of the management initiated and how it greatly influenced the skin wound healing in dogs. In conclusion, proper initial assessment of wounds and appropriate treatment through rigorous wound assessment and bandaging are critical to success in the wound healing and restoration of tissue integrity. This management intervention could be further investigated in animals in order to improve the quality of cutaneous wounds management

Keywords: Cutaneous wound; Para-chloroaniline solution; Idiopathic, Management; Polyethylene.

INTRODUCTION

Skin problems are among the most common reasons pets' owners seek veterinary interventions due to the discomforts experienced by the pets and aesthetics, which may be a sign of other underlying health problems (Orsted *et al.*, 2016). The most common causes of skin wounds in dogs are allergies from parasites like fleas, environmental allergies, and adverse food reactions (Chicharro-Alcántara *et al.*, 2018). Any skin injury (often chronic) whose underlying aetiology remains obscured despite methodical diagnostic approach is called idiopathic cutaneous wound (Breathnach *et al.*, 2008). Bacterial infection has been reported to be significant component of idiopathic cutaneous wound (Scott *et al.*, 2001). Most wounds management interventions aim at promoting wound healing, protection of wounds from the environment and interference by the patient, absorption of exudates, administration of topical medications, pain modulation, and supporting underlying structures (Fletcher, 2005; Bonnie, 2012). Different successes in treatment interventions necessitate continuous search to develop

wound management strategy that can enhance and accelerate healing of cutaneous wounds (Abu-Seida, 2015). This paper reports the management of diffusely necrotic cutaneous wound in a one-year-old male Terrier dog.

CASE PRESENTATION

Case history: A one-year-old male Terrier dog weighing 22 kg was presented to the Ahmadu Bello University Veterinary Teaching Hospital (ABUVTH), Zaria, Nigeria, with complaints of purulent discharge from sloughed off skin around the shoulder region. The dog was a hunting dog and the condition was first seen as a small area of skin discoloration with little suppurative discharges around the loin (noticed 2 weeks after returning from hunting) that progressed and extended to the shoulder region (without any intervention) 2 weeks prior to the clinical presentation.

Clinical examination: The clinical examination revealed normal vital parameters of 39.1°C, 90 beats/minute and 20 cycles/minute for temperature, pulse and respiratory rates, respectively. Extensive necrotized skin on the dorsum

extending from loin to the right shoulder and enlarged superficial lymph nodes (sub-mandibular, pre-scapular and popliteal).

Laboratory Investigation

Blood and wound swab samples were evaluated in the Clinical haematology and Microbiology laboratories of the

ABUVTH, respectively. The haematology result showed leucocytosis due to neutrophilia and monocytosis (Table 1). Staphylococcus aureus was isolated from the wound swab with antibiogram of Ciprofloxacin +, Penicillin ++, Streptomycin ++ and Gentamycin +++.

Table 1: Haematology Results on the First Day of Presentation

Parameters	Patient's Values	Reference Values ^b
HB(g/dl)	15.0	12-18
PCV (%)	45	37-55
WBC (×10 ⁹ /L)	19.80	6.0-17.0
Neutrophils (×10 ⁹ /L)	13.7 (69.2) ^a	3.6-13.1(60-77) ^a
Lymphocytes(×10 ⁹ /L)	2.6 (13.2) ^a	0.72-5.1(12-30) ^a
Monocytes(×10 ⁹ /L)	2.3 (11.6) ^a	0.18-1.7(3-10) ^a
Eosinophils(×10 ⁹ /L)	1.2 (6.0) ^a	0.12-1.7(2-10) ^a
Basophils(×10 ⁹ /L)	0 (0) ^a	Rare

a= Relative differential leukocyte counts in parenthesis

b= Source: (Sastry, 1983)

Case Management

Para-chloroaniline (PCA) was prepared by reconstituting 3.5 % sodium hypochlorite (Dakin's) solution (JIK^(R)- Reckitt Benckiserr, Ogun, Nigeria) and 0.3% chlorhexidine gluconate solution (Purit^(R)- Saro Life care limited, Lagos, Nigeria) in the proportion of 1:5 (Figure 1).



Figure 1: Topical antiseptics: Dakin's solution, chlorhexidine and povidone iodine

The PCA (at 0.05 %) was employed in the management of the condition. The surrounding (perimeter) of the wound was shaved and scrubbed with 0.3 % chlorhexidine, and then flushed with the 0.05 % PCA solution. The wound was dressed by wet-to-dry bandaging technique, utilizing gauze sponges moistened with sterile normal saline solution and held in place by the use of adhesive tape Procaine penicillin G (TROGE^(R)-Troge Medical GmbH Hamburg, Germany) at 25,000 IU/kg IM once daily x 1/2 and streptomycin sulphate (STREPA^(R)- North China Pharmaceutical Co., Ltd, Shijiazhuang city, China) at 10 mg/kg IM once daily x 1/2 were administered. The wound was again flushed with 0.05% PCA solution 24 hours later; then topical povidone iodine ointment (WOSAN^(R)-Jawa International Ltd, Lagos, Nigeria) was applied and held in place by dressing as in day

1. This was then re-evaluated 48 hours later. On day 4, an improvised non-adherent semi-occlusive (perforated) polythene membrane, which was cold-sterilised with the PCA solution and immediately impregnated with povidone iodine ointment (Figure 2), was applied at the wound-bandage interface before application of gauze bandage and dressed the same way as it was done on day 2.




Figure 2: An improvised non-adhesive protective polyethylene membrane (A) perforated (B) and impregnated with povidone iodine laid over a gauze (C)

This management protocol including wound evaluation was repeated every other day and maintained till 20th day of hospitalization (Figure 3).

From the 21st day to the end of 42nd day of hospitalization (Figures 4, 5, and 6), the wound was treated povidone iodine ointment only and the patient was later discharged from hospital on the 43rd day.

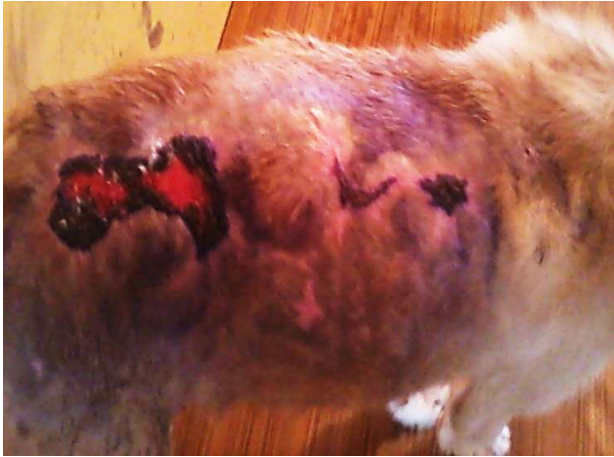

Figure 3: Healing of the necrotized idiopathic skin wound on the dorsum extending from loin to the right shoulder at day 20 of treatment

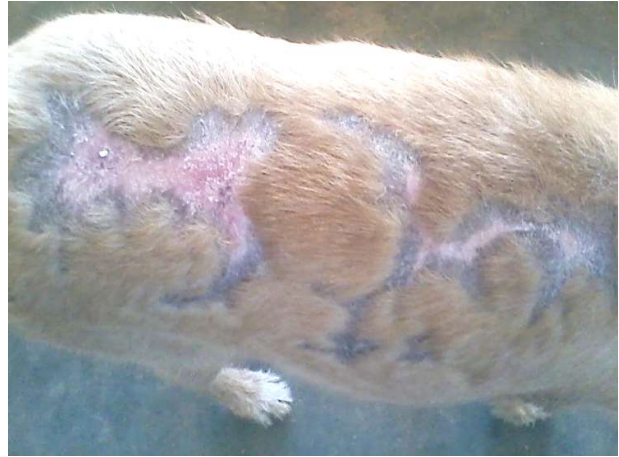

Figure 6: Healing of the necrotized idiopathic skin wound on the dorsum extending from loin to the right shoulder at day 42 of treatment

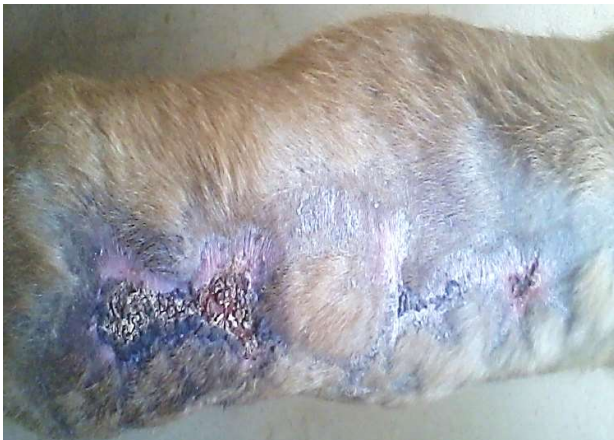

Figure 4: Healing process of the necrotized idiopathic skin wound on the dorsum extending from loin to the right shoulder at day 28 of treatment

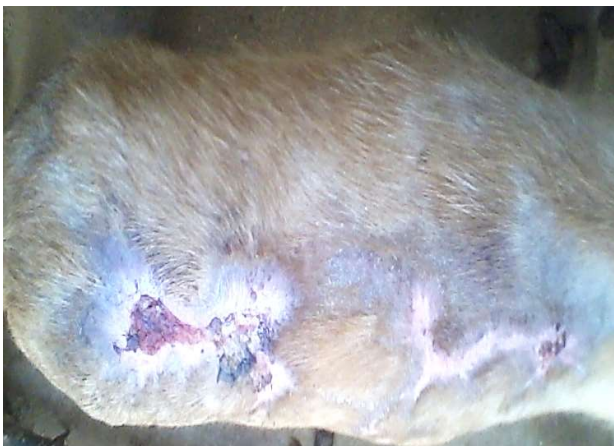

Figure 5: Healing process of the necrotized idiopathic skin wound on the dorsum extending from loin to the right shoulder at day 36 of treatment

DISCUSSION

Management of idiopathic cutaneous wounds with secondary bacterial infection is a common challenge in veterinary practice (Abu-Seida and Saleh, 2016), especially in hunting dogs, because of the nature, location and the extent of the injury, and attitude of the patient toward the injured site (Theoret, 2009). This is due to the risks of bacterial contamination, necrosis and the length of time it takes for the skin tissue to regenerate and form a scar (Theoret, 2009; Dieckmann *et al.*, 2010). Correct diagnosis and determination of the severity of the wound are essential for proper treatment (Pastar *et al.*, 2014). The use of systemic antibiotics (that is Procaine Penicillin G and streptomycin sulphate) was based on the antibiogram obtained. Wet-to-dry bandages aid in absorbing purulent exudates, removing loose debris and mechanical debridement of the wound. Improvised Non adherent semi-occlusive (perforated) polyethylene membrane with povidone iodine ointment at the wound-bandage interface protected the wound from adhering to the gauze bandage, kept the wound moist, served as vehicle for the topical antiseptic ointment and allowed fluid absorption into the gauze covering the wound. The effect of povidone iodine is due to the iodine ingredient which is rapidly lethal to microbes (bacteria) in the wound environment through disruption of protein and nucleic acid structure and synthesis. The antimicrobial effect is as the result of cell wall oxidation, and substitution of microbial contents with free iodine (Vogt *et al.*, 2006). The intervention technique used in this case enhanced and accelerated healing of the wound uneventfully similar to what Schunck *et al.* (2005) reported that artificial barrier repair with semi-occlusive foils in wounds reduced wound contraction and enhanced cell migration and reepithelization without irritation in mouse skin.

Conclusion

Initial assessment of wounds and appropriate treatment through rigorous nursing care and bandaging are critical to successful wound healing and restoration of tissue integrity.

This management intervention could be further investigated in animals in order to improve the quality of cutaneous wounds management.

Author Contributions

All authors contributed to the development of the manuscript at different levels, which included patient reception and hospitalization, clinical evaluation, management, sample collection and laboratory investigations, discussions, manuscript drafting, proof reading and editing.

Conflict of Interest

The authors declare that they do not have any conflict of interest.

REFERENCES

- Abu-Seida, M. A. (2015). Effect of propolis on experimental cutaneous wound healing in dogs. *Vet. Med. Int.* <http://dx.doi.org/10.1155/2015/672643>. Retrieved on 15/09/2019. 5:02 pm
- Abu-Seida, A. M. and Saleh, M. M. (2016). A gigantic cutaneous fibroadenoma in a dog," *Asian J. Anim. Sci.* 10(1): 113–119.
- Bonnie, G. C. (2012). Bandages and Drains. In: *Veterinary Surgery: Small Animal*. Tobias, K. M. and Johnston, S. A. (eds). Saunders, an imprint of Elsevier Inc. St. Louis, Missouri, U.S.A. Pp. 221-230.
- Breathnach, R. M., Fanning, S., Mulcahy, G, Bassett, H. F. and Jones, B. R. (2008). Canine pododermatitis and idiopathic disease. *Vet. J.*, 176: 146-157.
- Chicharro-Alcántara, D., Mónica, R., Elena, D., José, M. C., Belén, C., Pau, P. and Joaquín, J. S. (2018). Figurelet Rich Plasma: New Insights for Cutaneous wound healing management. *J. Funct. Biomater.* 1-20.
- Dieckmann, C., Renner, R., Milkova, L. and Simon, J. C. (2010). Regenerative medicine in dermatology: Biomaterials, tissue engineering, stem cells, gene transfer and beyond. *Exp. Dermatol.* 19: 697–706.
- Fletcher, J. (2005). Understanding wound dressings: Alginates. *Nurs Times*, 101:53
- Orsted, H. L., Keast, D. and Forest-lalande, L. (2016). Basic Principles of Wound Healing. An understanding of the basic physiology of wound healing provides. *Wound Care Can.* 9(2): 1-5.
- Pastar, I., Stojadinovic, O., Yin, N. C., Ramirez, H., Nusbaum, A.G., Sawaya, A., Patel, S. B., Khalid, L., Isseroff, R. R. and Tomic-Canic, M. (2014). Epithelialization in wound healing: A Comprehensive Review. *Adv. Wound Care*, 3: 445-464.
- Sastry, G. A. (1983). *Veterinary Clinical Pathology*, 6th ed. C.B.S. Publishers and Distributers, Delhi, pp. 4-35.
- Schunck, M., Neumann, C. and Proksch, E. (2005). Artificial barrier repair in wounds by semi-occlusive foils reduced wound contraction and enhanced cell migration and reepithelization in mouse skin. *J. Invest. Dermatol.* 125(5): 1063–1071.
- Scott, D. W., Miller, W. H. and Griffen, C. E. (2001). *Small Animal Dermatology*, 6th ed. W. B. Saunders, Philadelphia, USA, pp. 304-306 and 667-779.
- Theoret, C. (2009). Tissue engineering in wound repair: The 3R's—Repair, replace, regenerate. *Vet.Surg.* 38: 905–913.
- Vogt, P. M., Reimer, K., Hauser, J., Rossbach, O., Steinau, H. U., Bosse, B., Muller, S., Schmidt, T. and Fleischer, W. (2006). PVP-iodine in hydrosomes and hydrogel: a novel concept in wound therapy leads to enhanced epithelialization and reduced loss of skin grafts. *Burns*; 32(6): 695–705.